

Dr.Rekha Srinivasan.B.H.M.S

Homoeopathic Physician

PREVENTION OF CONGENITAL AND HEREDITARY DEFECTS THROUGH HOMOEOPATHY

Should this paper set you a Thinking and call forth a discussion and an Explanation of opinion and also elicit the experience of those shown grey in the service of scientific therapeutics, I shall learn much there from

These are the initial words of Dr Burnet's paper on prevention of congenital defects- hare lip cleft palate. This inspired me to think about the field of Homeopathic prevention in hereditary disorders. I am now convinced that hereditary diseases are prevented by Homeopathy alone and some of the congenital defects have to be rectified surgically.

I think We Homoeopaths should take up this for research purpose and establish the supremacy of Homoeopathy in this most important field of Health sciences. I plead to Institutions to take up this cause since one of My clients could not do the genetic mapping due to Financial constrains, even though I have treated that baby to prevent Duchene's Muscular Dystrophy. I am in dark since it appeared in Males in that family at around 13-14 years of age. That baby now is of 2 years of age and his parents are unable to carry out those Expensive tests.

And this subject is endearing to me as a woman. Here I want to put forward two similar cases where the Homoeopathy heals defects of foetuses aesthetically. But before that I want to tell the flashback so as to justify the supremacy of Homeopathic intervention.

One of my beneficiaries had a female child in the year 2002. That baby was diagnosed clinically as suffering from Hydrocephalous. Naturally her head was ever enlarging. That child developed cerebral palsy and her milestones which were altogether slow now stopped and reversed. At the age of 10 months she had neither developed head control nor can turn on her abdomen and no need to say she could not sit or walk. But before that infant was subjected to series of tests and scans she parted from them due to RDS at 11 months of age.

From then they were afraid of going for another baby lest hydrocephalus reappears in next issue. Incidentally I was reading this very paper which instigated me to experiment. I had to trust Pioneers of Homoeopathy in treating such cases.

Raj Homoeo Clinic

145, Kutchery Road, Mylapore, Chennai-600 004.Tamilnadu, India

Dr.Rekha Srinivasan.B.H.M.S

Homoeopathic Physician

After detailed case taking the mother was counselled on several matters. She was advised to take Folic Acid supplement till 15wks of pregnancy as well as Natural and Healthy balanced diet.

Treatment given is as detailed below

Calc sulph 6c

Calc flour 6c} as suggested by Burnett for bony
reunion with out any defects

Kali phos 6c,calc phos 6c

Ferr phos 6c ,Mag phos 6c,Nat phos 6c} On nutritive plane

Every day one pills each from all of those drugs. (Not a combination)

After she conceived I told her to take only these tissue salts no vitamins, calcium or iron pills, as they caused overall aggravation of her symptoms. She was comfortable off with them.

(I Insist again on prescription of folic acid peri conception, especially for pregnant ladies who will have vomiting and reduced intake of food).

Apart from this till delivery usual constitutional treatment according to one's constitution. In this case it was pitutarin 30 for non appearance of pains in previous deliveries. Secale cor 6 and 30 in one weeks gap (retention of placenta in previous delivery).

That child is hyperactive with big head and thin stature, under weight, very tubercular in nature. But had milestones appeared at proper age and declared healthy by allopathic doctors as well.

In 2007 I was approached by one of my clients, who is working as a Lecturer in a reputed college. She asked me whether there is any treatment to prevent defects in the baby before it is actually born. I asked her to bring in all the related reports. That lady has undergone two MTP's because of the malformation of babies face and both were developing hydrocephalous. She evidently was very upset and willing to have a normal child if she could plan to have one more pregnancy. Already she was under allopathic care in a famous fertility clinic in Chennai. They had put her on routine fertility drugs although she had no difficulty in conceiving. They were treating with Folic acid to prevent Hydrocephalous but they had any answer neither for facial anomaly found in previous foetus nor for that cardiomegaly.

Raj Homoeo Clinic

145, Kutchery Road, Mylapore, Chennai-600 004.Tamilnadu, India

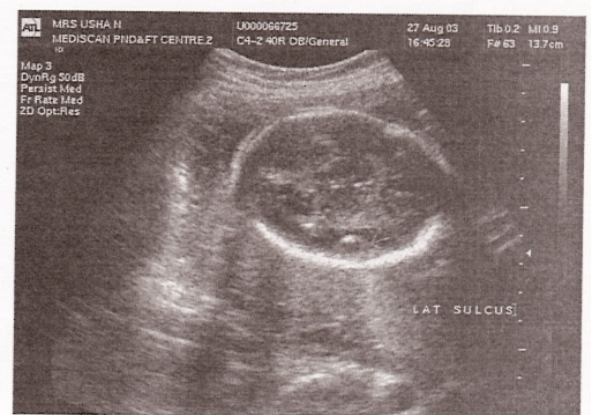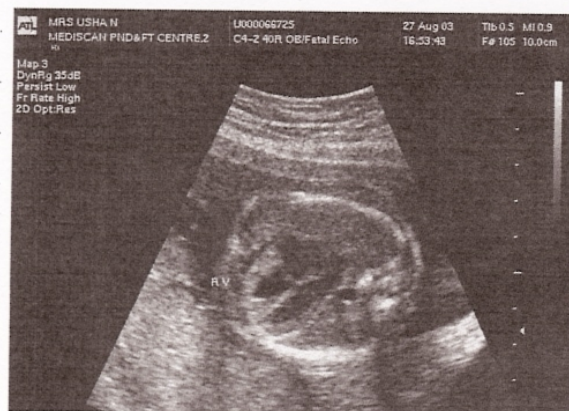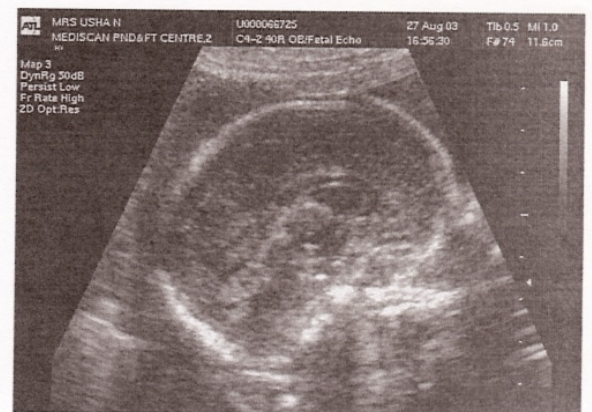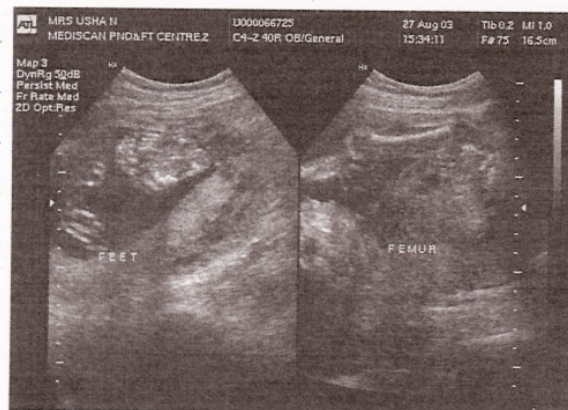
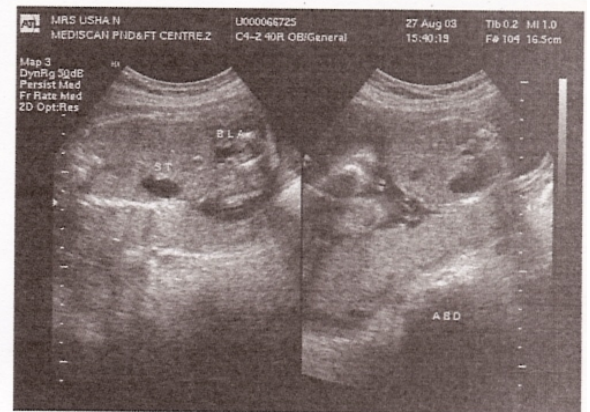
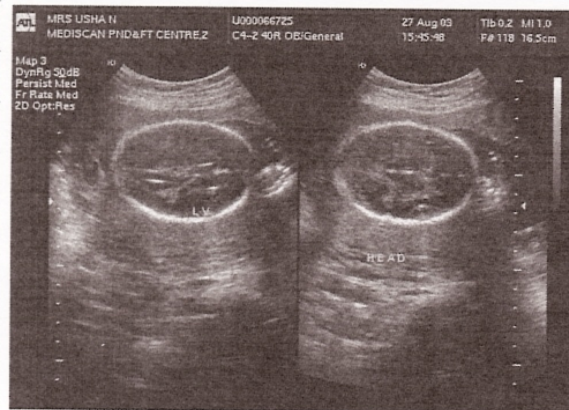
Dr.Rekha Srinivasan.B.H.M.S

Homoeopathic Physician

Mediscan Prenatal Diagnosis & Fetal Therapy Centre

203,AVVAI SHANMUGAM SALAI,1st ROYAPETTAH,CHENNAI-600014

Patient Name	MRS. USHA NAIDU ANANTHA PADMANABAN (1072/03)	Patient Age / Sex	30 yrs / Female
Patient Id	U000066725	Ethnic Group	
Referral Doctor	LAKSHMI J.S	Visit Date	Visit # 02: 27 Aug 2003



Dr.Rekha Srinivasan.B.H.M.S

Homoeopathic Physician



Directors
Dr. S. Suresh
Dr. Indrani Suresh

Consultants
Dr. Bharathi Anand
Dr. Nithyakalyani

Sr. Sonograph
Mrs. Devaki Gop
Mrs. Vijayalaksh

Thursday 28 August

Page#

IMPRESSION

Single intrauterine gestation corresponding to a gestational age of 24 - 25 weeks.

CORRECTED EDD - 14/12/2003.

Gestational age assigned as per PREVIOUS SCAN.

Placenta - Posterior.

Lower limit of placenta measured 5.6 cms from the os.

Liquor - Normal.

UMBILICAL VEIN VARIX SEEN.

CENTRAL NERVOUS SYSTEM : -

FOURTH VENTRICLE APPEARED DILATED.

CYST SEEN IN THE MIDLINE IN THE INFRA TENTORIAL REGION -SUGGESTIVE OF DANDY WALKER VARIANT.

CARDIOMEGALY PRESENT.

(Dr. S Suresh .)
Encl. Photographs (13).

hé

Raj Homoeo Clinic

145, Kutchery Road, Mylapore, Chennai-600 004.Tamilnadu, India

Dr.Rekha Srinivasan.B.H.M.S

Homoeopathic Physician



Fetal Care Research Foundation

Managing Trustees

Dr. S. Suresh
Dr. Indrani Suresh

Consultant Pathologists

Dr. S. Lata
Dr. Kamakshi Kartik

Clinical Dysmorphologist


Dr. Sujatha Jagadeesh

Final Impression

- 1. MALE FETUS OF 25 -26 WEEKS
GESTATIONAL AGE
- 2. MILD FACIAL DYSMORPHISM
- 3. CNS - DILATED FOURTH VENTRICLE
AND CEREBELLAR HYPOPLASIA
- 4. MODERATE PLACENTAL INSUFFICIENCY

Suggested

- 1. PREPREGNANCY COUNSELLING
- 2. PERICONCEPTIONAL FOLIC ACID



Dr. S. Lata

Pathologist

15/12/2003

Dr. Kamakshi Kartik

Pathologist

B0657


Page 2 of 2

15 December 2003

Old No.113-B New No.203, Avvai Shanmugam Road, Royapettah, Chennai 600 014. Ph.: 28116965, 28111687, 28116232
Fax : 91-44-28112135. E.Mail:ssuresh@vsnl.com

Raj Homoeo Clinic

145, Kutchery Road, Mylapore, Chennai-600 004.Tamilnadu, India



Fetal Care Research Foundation

Managing Trustees

Dr. S. Suresh

Dr. Indrani Suresh

Consultant Pathologists

Dr. S. Lata

Dr. Kamakshi Kartik

Clinical Dysmorphologist

Dr. Sujatha Jagadeesh

**POST-MORTEM REPORT OF FETUS OF USHA NAIDU ANANTHA
PADMANABHAN**

MATERNAL DETAILS

Autopsy ID	- B1512
Name	- Mrs.Usha Naidu Anantha Padmanabhan
Age / Sex	- 32/Female
Referral Doctor	- Dr.J. S. Lakshmi
LMP Date	- 17/12/2004
Gravida	- III
Para	- I
Live	- I
Abortion	- I
Consanguinity	- Nil
Previous H/o. Anomalies	- I - FTND, Male, 4 yrs, A & H II- TOP at 24 - 25 weeks for Dandy Walker Variant. Autopsy done at mediscan IMP: Facial dysmorphism, dilated fourth ventricle, cerebellar hypoplasia and placental dysfunction III - PP
USG Scan Done	- 16/04/2005
USG Scan No.	- U 66725
Scan Details	- SINGLE INTRA UTERINE GESTATION OF 17 - 18 WEEKS. PLACENTA POSTERIOR. LIQUOR NORMAL. CNS: DILATED FOURTH VENTRICLE. CEREBELLUM APPEARED NORMAL. SUGGESTIVE OF DANDY WALKER VARIANT

Dr.Rekha Srinivasan.B.H.M.S

Homoeopathic Physician



Fetal Care Research Foundation

Managing Trustees

Dr. S. Suresh
Dr. Indrani Suresh

Consultant Pathologists

Dr. S. Lata
Dr. Kamakshi Kartik

Clinical Dysmorphologist

Dr. Sujatha Jagadeesh

Fetogram Report

- Normal study

Final Impression

- 1. FEMALE FETUS OF 19 WEEKS
GESTATIONAL AGE
- 2. CNS :
 - DANDY WALKER MALFORMATION
WITH DILATED LATERAL VENTRICLES
- 3. PLACENTAL OEDEMA

Suggested

- 1. PREPREGNANCY COUNSELLING
- 2. PERICONCEPTIONAL FOLIC ACID



Dr.S. LATA

Senior Consultant Pathologist

03/06/2005

B1512

Page 1 of 1

03 June 2005

Old No.113-B New No.203, Avvai Shanmugam Road, Royapettah, Chennai 600 014. Ph.: 28116965, 28111687, 28116232
Fax : 91-44-28112135. E.Mail:ssuresh@vsnl.com

I assured her that Homeopathy can help her and mentioned her another case of mine and double assured her that I will not leave any stone unturned from my behalf to help her.

Raj Homoeo Clinic

145, Kutchery Road, Mylapore, Chennai-600 004.Tamilnadu, India

Dr.Rekha Srinivasan.B.H.M.S

Homoeopathic Physician

I took her case repeterised and started treatment with pulsatilla 6 and then 30. After 2 1/2 months of it along with the above mentioned schedule she conceived. That is the time when the real trial begun. I gave medicines on symptom similarity and since the gravity of the case is very high and also I did not want to take any chances, I took that lady to Dr. Aleem for expert opinion and whenever major issues arose I consulted him and he advised me willingly. He went through the reports intently. After reading those reports in detail, on the basis of facial dysmorphisms in that previous foetus since that tendency is syphilitic in nature he suggested me to give ***Ac flour, which is chronic of puls and syphilitic in nature.***

We passed that “19th week ultra sound scan” with flying colours. Scan taken around that period in the previous Pregnancies had revealed the defects and MTP was conducted. So, it was very crucial stage for this case.

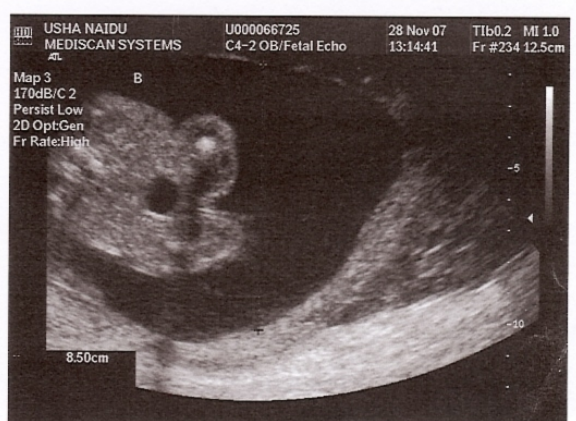
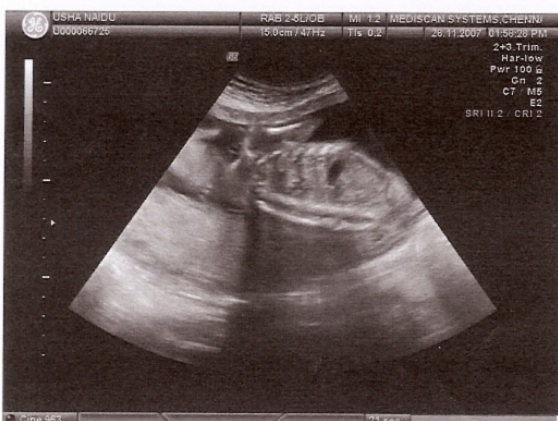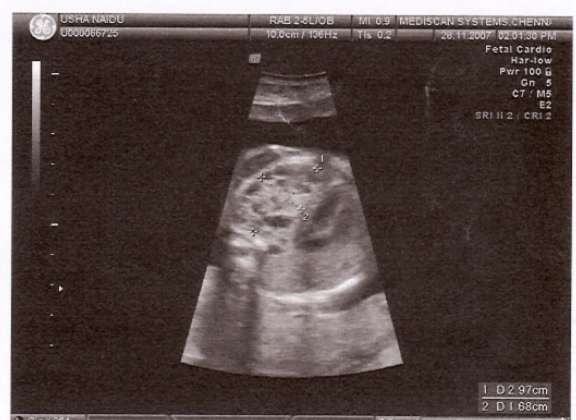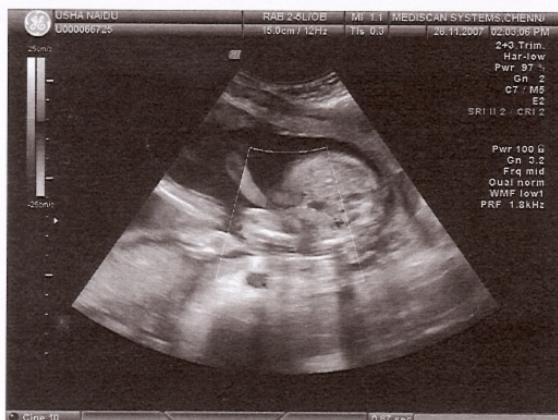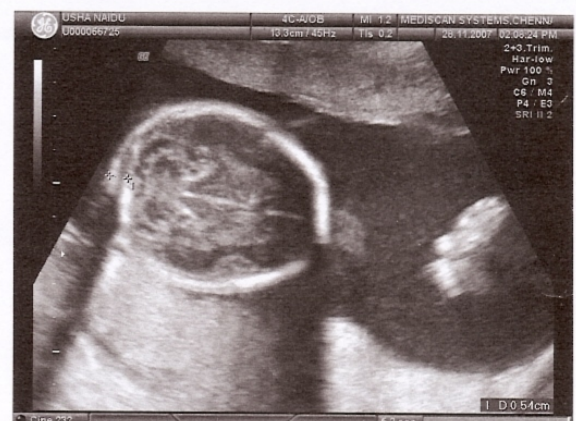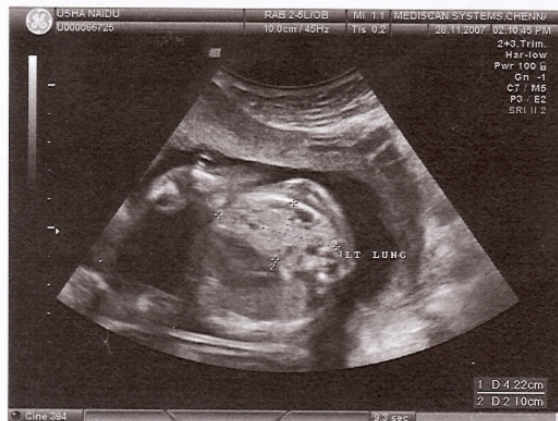Raj Homoeo Clinic

145, Kutchery Road, Mylapore, Chennai-600 004.Tamilnadu, India

Dr.Rekha Srinivasan.B.H.M.S

Homoeopathic Physician

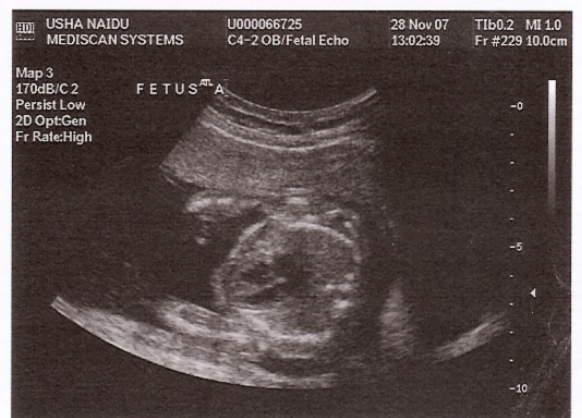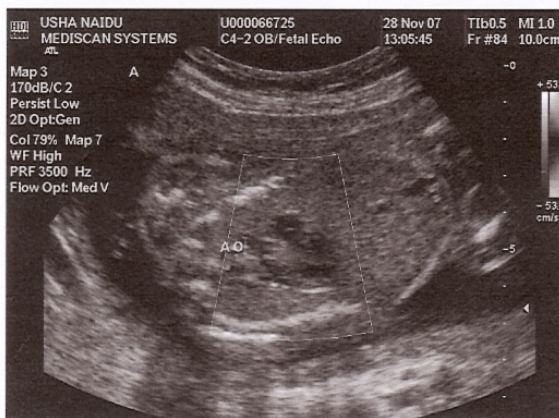
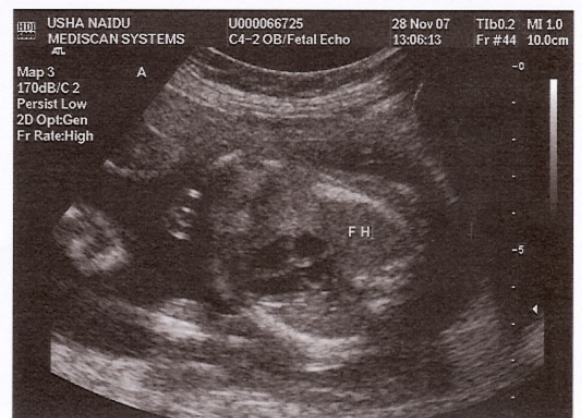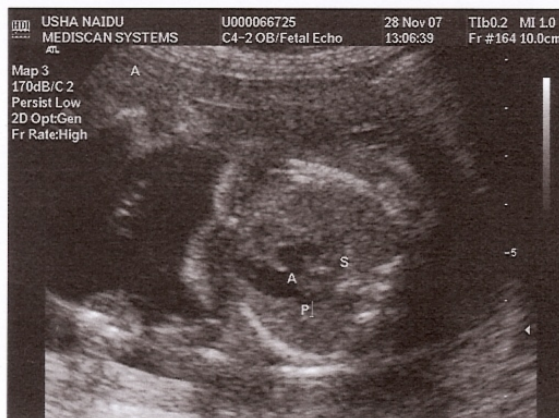
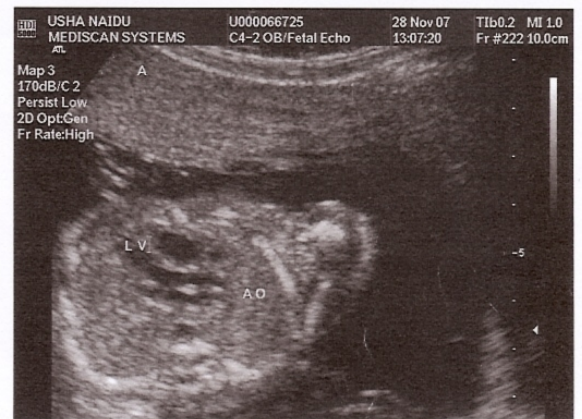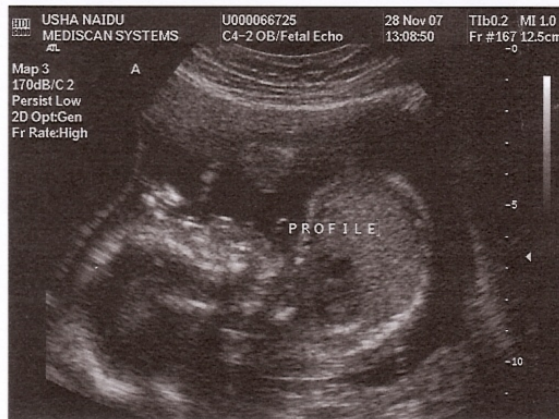Mrs. USHANAIDU ANANTHAPADMANABAN(1072/03) / U000066725 / 28/11/2007 / Visit No 8



Dr.Rekha Srinivasan.B.H.M.S

Homoeopathic Physician

Mrs. USHANAIDU ANANTHAPADMANABAN(1072/03) / U000066725 / 28/11/2007 / Visit No 8



Page #3 - 29/11/07 01.03 PM

Raj Homoeo Clinic

145, Kutcheri Road, Mylapore, Chennai-600 004.Tamilnadu, India

Dr.Rekha Srinivasan.B.H.M.S

Homoeopathic Physician

MediScan

Ultrasound | Fetal Care | Genetics

No: 197, Dr Natesan Road, Mylapore, Chennai - 600 004. INDIA
Tel: +91 - 44 - 2466 3232 (10 lines) , Fax: +91 - 44 - 2498 8226
Web: www.mediscansystems.org



Patient Name	Mrs. USHANAIDU ANANTHAPADMANABAN(1072/03)	Age/Sex	34 Years / Female
Patient ID	U000066725	Visit No	8
Referred by	Dr. JEYARANI KAMARAJ	Visit Date	28/11/2007
LMPDate	24/06/2007	LMP EDD	30/03/2008

OB - 2/3 Trimester Scan Report

Indication(s)

Previous anomalies
GROWTH

Real time B-mode ultrasonography of gravid uterus done.

Route: Transabdominal

Twin intrauterine gestation

Type of twinning

Dichorionic Diamniotic Twin
Membrane seen between fetuses

Maternal

Cervix measured 3.4 cms in length

Fetus A

Survey

Placenta - Anterior
Liquor - Normal
Umbilical Cord - Three vessel cord
Fetal activity seen
Cardiac activity normal.

Fetal Biometry

Mediscan	Mediscan	Mediscan	Mediscan
BPD 54 mm 22 weeks	HC 192 mm 21 weeks 6 Days	AC 171 mm 22 weeks 1 Days	FL 39 mm 22 weeks
*	*	*	*
5% 50% 95%	5% 50% 95%	5% 50% 95%	5% 50% 95%

Cephalic index - 79 Normal range 75-85%

Extended Biometry

Foot Length : 39.0 mm
TCD : 23.0 mm

Dr.Rekha Srinivasan.B.H.M.S

Homoeopathic Physician

MediScan

Ultrasound | Fetal Care | Genetics

No: 197, Dr Natesan Road, Mylapore, Chennai - 600 004, INDIA
Tel: +91 - 44 - 2466 3232 (10 lines) , Fax: +91 - 44 - 2498 8226
Web: www.mediscansystems.org



Patient Name	Mrs. USHANAIDU ANANTHAPADMANABAN(1072/03)	Age/Sex	34 Years / Female
Patient ID	U000066725	Visit No	8
Referred by	Dr. JEYARANI KAMARAJ	Visit Date	28/11/2007
LMPDate	24/06/2007	LMP EDD	30/03/2008

Impression

Twin gestation corresponding to a gestational age of 22 Weeks 3 Days

Gestational age assigned as per LMP

Fetus (A)

Placenta - Anterior

Liquor - Normal

Estimated fetal weight according to BPD,HC,AC,FL :- 484 + / - 48.4 gms.

Fetus (B)

Placenta - Posterior

Liquor - Hydramnios

Estimated fetal weight according to BPD,HC,AC,FL :- 452 + / - 45.2 gms.

DICHORIONIC DIAMNIOTIC TWINS.

FETUS A : - NORMAL.

NORMAL DOPPLER STUDY.

DETAILED STUDY OF FETAL HEART DOES NOT REVEAL ANY MALFORMATION DETECTABLE BY ULTRASOUND DURING THIS PERIOD OF GESTATION.

FETUS B : -


LIQUOR - HYDRAMNIOS.

PICTURE IS SUGGESTIVE OF ADENOMATOID MALFORMATION OF THE LEFT LUNG - TYPE I MACROCYSTIC VARIETIES.

NORMAL DOPPLER STUDY.

DETAILED STUDY OF FETAL HEART DOES NOT REVEAL ANY MALFORMATION DETECTABLE BY ULTRASOUND DURING THIS PERIOD OF GESTATION.

Suggested repeat scan after 4 weeks for reassessment.


SURESH.S DR


BHARATHI ANAND DR

Raj Homoeo Clinic

145, Kutchery Road, Mylapore, Chennai-600 004.Tamilnadu, India

Dr.Rekha Srinivasan.B.H.M.S

Homoeopathic Physician

report attached)

Fortunately or otherwise she got a twin pregnancy, because of an allopathic fertility Drug .She had lots of dilemma whether to continue with that pregnancy or to terminate it, as she was really scared of facing that mental trauma of another MTP due to anomalies .But I Counselling her with compassion, gave **Arnica** (fear of approaching things). Also **Pulsatilla** helped to overcome that depression due to pregnancy, vomiting and loss of appetite.

All through **AC flour 6c** dilution daily was continued. Meanwhile her minor troubles were taken care with phase remedies like Ruta g 6 for severe leg pains, mephitis 6 for dry cough usually single doses.

At third trimester she casually mentioned that she was on Anticoagulants. On Further interrogation I came to know that she is diagnosed as having Antiphospholipid (A p L) syndrome due to placental anomaly in previous pregnancy although Anticardiolipin is normal and lupus anticoagulant negative. She took heparin injections for the whole of her pregnancy . I treated her with **Arnica 6c** daily in dilution form as an anticoagulant indeed.

She was on **Sulphur 200** single dose **Thuja200** single dose and **Merc sol 200** at one week's gap and **Caulophyllum** 200 daily at the end of third trimester. But she could not have normal delivery due to twin Pregnancy . She delivered Healthy twin girls by **Lscs** on 18 of

Raj Homoeo Clinic

145, Kutchery Road, Mylapore, Chennai-600 004.Tamilnadu, India

Dr.Rekha Srinivasan.B.H.M.S

Homoeopathic Physician

march 2008.



ST.ISABEL` S HOSPITAL

NO 49. Oliver Road, Mylapore, Chennai - 600 004

Phone .No : 044-24991081/82/83, Fax .No: 044- 24984776

DISCHARGE SUMMARY

Patient's Name : Mrs. Usha Naidu. S
Age/Sex : 34yrs / F
IP .No : V 3129
Consultant : Dr. J. S. Lakshmi
Ward : C-Up
DOA : 15/03/08
DOD : 24/03/08
Blood Group : B - Positive

FINAL DIAGNOSIS :

EMERGENCY LSCS / TWIN GESTATION / BOH / APL SYNDROME

PRESENTING COMPLAINTS & HISTORY :

G4 P1 L1 A2 LMP: 24/06/07 EDD: 30/03/08, twin gestation
Admitted for safe confinement
I – FTND, male, 7years, alive & healthy
II – MTP (24-25weeks) dandy walker variant – 2001
III – MTP (17-18weeks) dandy walker variant – 2005
IV – PP
Clomid induction
Variant detected border line APL syndrome
Put on Ecosprin & Clevarine throughout pregnancy
Had ovulation induction agents
Not a known diabetic or hypertensive
H/o cataract surgery right eye

O/E:

Patient mildly anaemic, afebrile
Pulse-88/min BP-110/70 mm of Hg

Raj Homoeo Clinic

145, Kutchery Road, Mylapore, Chennai-600 004.Tamilnadu, India

Dr.Rekha Srinivasan.B.H.M.S

Homoeopathic Physician

CVS / RS – NAD

P/A – uterus overdistended, multiple fetal parts, both FH good

PV – Not done

INVESTIGATION :

Hb-10.7, PCV-33%, HbsAg, HIV-Negative, VDRL-Non Reactive, FBS-93, PPBS-101

05/12/07: GTT: 85/143/123/111

16/03/08: Hb-13.2, PCV-36%, Platelet-2.25lakhs, PT-13', APTT-30"

USG: 06/08/07: Small gestational sacs – two in number

04/10/07: Dichorionic diamniotic twins, 14weeks 4days

28/11/07: Left lung enlarged with multiple cystic areas of varying sizes – Twin B

14/12/07: 24weeks 5days, Twin A – normal, Twin B – Type II cystic adenomatoid

20/02/08: 34weeks 3days, Fetus A – normal, Fetus B – Regression of cysts in left lung compared with previous scan

17/03/08: 38weeks 1day, Findings confirmed as on previous scan

PROCEDURE NOTES:

On 18/03/08, patient developed mild contractions,
PV-Cx 75% effaced, Os 4cm dilated, Vx at -2, BOM+

Patient taken up for Emergency LSCS

Indication: Twin gestation / BOH / APL syndrome

Per op findings: Emergency LSCS on 18/03/08 at 8.30am

1st twin extracted by vertex

2nd twin extracted as breech

Twin A

Female Term

Weight – 2.6kg

Time – 8.45am

Date – 18/03/08

Apgar – 9/10

Twin B

Female Term

Weight – 2.6kg

Time – 8.46am

Date – 18/03/08

You should see to believe it as both girls are very cute and active .But one of the girls has cysts in her lungs .Even though it is not Life threatening their parents are anxious to treat it. In fact when in uteri that defect was treated with **Apis 6c** dilution everyday the size of cyst got reduced but was not cured. After Delivery that baby is on anti sycotic Rx **Thuja200** single doses with a week's gap for a month. [That cyst was operated upon successfully when the baby reached 06 months of age]

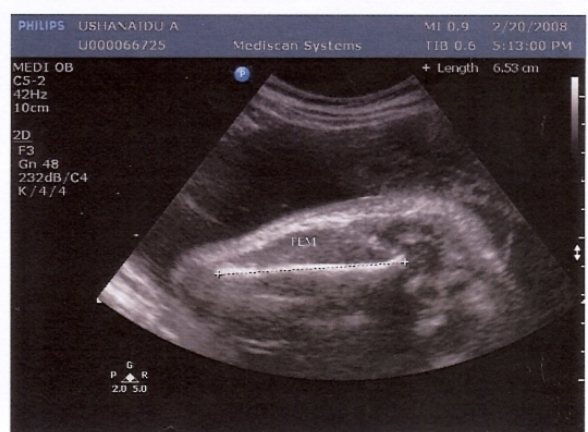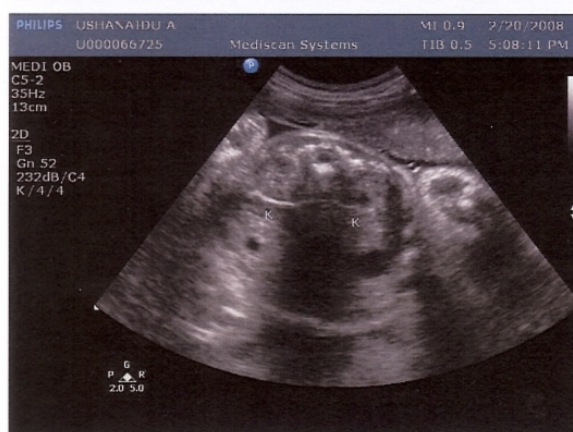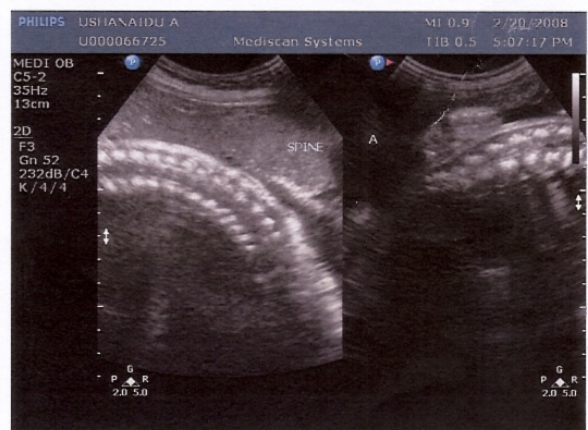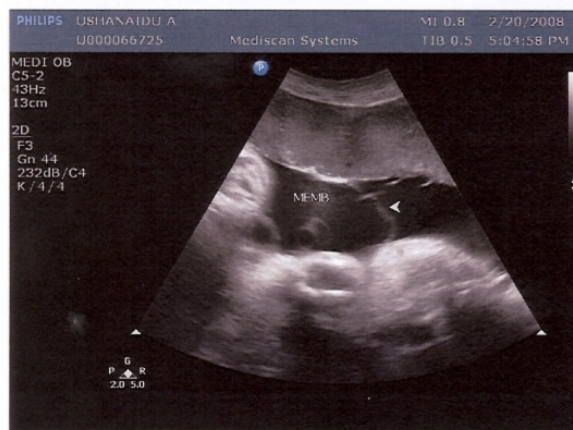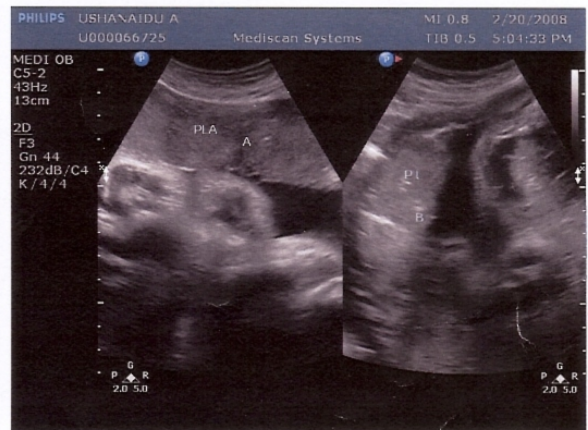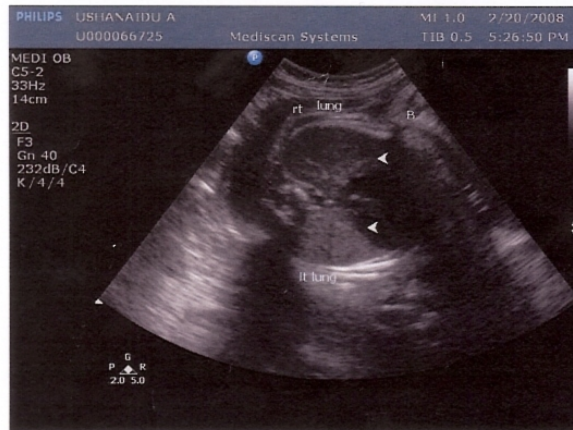Raj Homoeo Clinic

145, Kutchery Road, Mylapore, Chennai-600 004.Tamilnadu, India

Dr.Rekha Srinivasan.B.H.M.S

Homoeopathic Physician

Patient Name	Mrs. USHANAIDU ANANTHAPADMANABAN(1072/03)	Age/Sex	34 Years / Female
Patient ID	U000066725	Visit No	11
Referred by	Dr. JEYARANI KAMARAJ	Visit Date	20/02/2008



Page #1 - 21/02/08 04:20 PM

Raj Homoeo Clinic

145, Kutcheri Road, Mylapore, Chennai-600 004.Tamilnadu, India

Dr.Rekha Srinivasan.B.H.M.S

Homoeopathic Physician

MediScan

Ultrasound | Fetal Care | Genetics

No: 197, Dr Natesan Road, Mylapore, Chennai - 600 004. INDIA
Tel: +91 - 44 - 2466 3232 (10 lines) , Fax: +91 - 44 - 2498 8226
Web: www.mediscansystems.org



Patient Name	Mrs. USHANAIDU ANANTHAPADMANABAN(1072/03)	Age/Sex	34 Years / Female
Patient ID	U000066725	Visit No	11
Referred by	Dr. JEYARANI KAMARAJ	Visit Date	20/02/2008
LMPDate	24/06/2007	LMP EDD	30/03/2008

Impression

Twin gestation corresponding to a gestational age of 34 Weeks 3 Days

Gestational age assigned as per LMP

Fetus (A)

Presentation - Cephalic

Placenta - Anterior

Liquor - Normal

Estimated fetal weight according to BPD,HC,AC,FL :- 2049 + / - 204.9 gms.

Fetus (B)

Presentation - Transverse lie with head in left hypochondrium.

Placenta - Posterior

Liquor - Normal

Estimated fetal weight according to BPD,HC,AC,FL :- 2048 + / - 204.8 gms.

DICHORIONIC DIAMNIOTIC TWINS.

FETUS A : - NORMAL.

FETUS B : - AS COMPARED TO PREVIOUS SCAN, THERE IS REGRESSION OF THE CYSTS IN THE UPPER LEFT LUNG.

SUGGESTED POSTNATAL SCAN FOR 2ND BABY (FETUS B).

INDRANI SURESH DR

NITHYA KALYANI DR

Raj Homoeo Clinic

145, Kutchery Road, Mylapore, Chennai-600 004.Tamilnadu, India

Dr.Rekha Srinivasan.B.H.M.S

Homoeopathic Physician

Both Girls are developing normally and on Homoeopathic treatment for all infantile troubles.

This is a Perfect case of Hailing Homoeopathy's insurmountable supremacy in treating hereditary taints and congenital defects in utero or in infants. The beauty lies in the fact that even then Homoeopathic Laws were followed unmistakably.

The Hydrocephalus is basically tubercular (psora +syphilis) and facial malformation is Syphilitic in nature, it got reduced to Cysts in Lungs which is Sycotic in nature. So, it is evident that even Pathological prescription need not go against Principles.

For argument we may say that those babies would have been normal without Homoeopathic treatment, but evidence shows that it is not a valid point. As in both cases the ladies had first issue normal one. Second pregnancy revealed developmental disorders. Third pregnancy was no better without treatment in second mentioned case. In the first mentioned case normal baby was born after homoeopathic treatment. Homoeopathic Intervention alone took that fourth pregnancy in that second mentioned case to full term and without anomalies, it is not a spontaneous cure.

Hail Homoeopathy

Raj Homoeo Clinic

145, Kutchery Road, Mylapore, Chennai-600 004.Tamilnadu, India